

Prenatal Diagnosis and Management of Advanced Abdominal Pregnancy in Dr. Moewardi Hospital Surakarta: A Case Series

Ucti Akbar¹⁾, Nutria Widya Purna Anggraini^{1,2)}, Eric Edwin Yuliantara^{1,2)},
Muhammad Adrianes Bachnas^{1,2)}, Robert Ridwan^{1,2)}, Sri Sulistyowati^{1,3)}

¹⁾Medical Faculty, Universitas Sebelas Maret

²⁾Division of Fetomaternal, The Division of Obstetrics and Gynecology /
Regional Public Hospital of Dr. Moewardi Surakarta

³⁾Division of Fetomaternal, The Division of Obstetrics and Gynecology /
Hospital of Universitas Sebelas Maret

ABSTRACT

Background: The abdominal pregnancy is a pregnancy anywhere in the abdominal cavity other than the tube, ovary, and broad ligament. Abdominal pregnancy has 7.7 times greater risk than tubal pregnancy and 90 times greater than intrauterine pregnancy. This study aims to reveal the diagnosis and treatment of abdominal pregnancy in Dr. Moewardi Hospital Surakarta.

Subjects and Method: This was a case series study conducted at Dr. Moewardi Hospital Surakarta. This study report three cases of advanced abdominal pregnancy at Dr Moewardi Hospital (2019 – 2020), that consisted of two cases of advanced abdominal pregnancy to term, and one advanced abdominal pregnancy with acute abdomen.

Case presentation: Case 1 (it was found abdominal pregnancy at 30 weeks), the condition of the mother and the fetus was good, the pregnancy was continued until the gestational age was term. The patient was given corticosteroids for lung maturation and magnesium sulfate for neuro-protection. Case 2 (an abdominal pregnancy was found at term), it was decided to immediately terminate it with good preoperative preparation. Both patients in case 1 and case 2 had good result in both the mother and the fetus. The placenta was left in situ in both cases to prevent massive bleeding and injury to the gastrointestinal organs. Case 3 (advanced abdominal pregnancy with acute abdominal symptoms) decided to undergo an emergency laparotomy and removal of the placenta.

Conclusion: Abdominal pregnancy must be diagnosed and managed properly to reduce maternal mortality and morbidity. In advanced abdominal pregnancy, it could be considered to continue the pregnancy until the term. The placenta management of in situ without methotrexate might be considered in cases of abdominal pregnancy.

Keywords: abdominal pregnancy, prenatal diagnosis, treatment

Correspondence:

Ucti Akbar. Departement of Obstetrics & Gynaecology, Faculty of Medicine, Universitas Sebelas Maret/ Dr. Moewardi Hospital, Surakarta, Jl. Kolonel Sutarto, Surakarta 57126, Central Java. Email : druchtiakbar@gmail.com. Mobile: 081397167176.

Cite this as:

Akbar U, Anggraini NWP, Yuliantara EE, Bachnas MA, Ridwan R, Sulistyowati S (2021). Prenatal Diagnosis and Management of Advanced Abdominal Pregnancy in Dr. Moewardi Hospital Surakarta: A Case Series. *J Matern Child Health*. 05(02): 516-522. <https://doi.org/10.26911/thejmch.2021.06.05.01>.



Journal of Maternal and Child Health is licensed under a Creative Commons Attribution-NonCommercial-ShareAlike 4.0 International License

BACKGROUND

The abdominal pregnancy is a pregnancy anywhere in the abdominal cavity other than the tube, ovary, and broad ligament (Jabbar et al., 2018). Advanced abdominal pregnancy is defined as an abdominal pregnancy that develops beyond 20 weeks of gestation (Gilani and Syed, 2019). Cavity of Douglas is the most frequent site of abdominal pregnancy followed by mesosalpinx and omentum. Abdominal pregnancy occurs in 1–1.5% of ectopic pregnancies with an incidence of 1: 8,000 - 10,000 pregnancies (Jabbar et al., 2018; Gilani and Syed, 2019).

Abdominal pregnancy has 7.7 times greater risk than tubal pregnancy and 90 times greater than intrauterine pregnancy. Maternal mortality is around 0.5% - 18% and perinatal mortality is around 40 - 95% (Hailu et al., 2017). Maternal morbidity is caused by bleeding, infection, anemia, disseminated intravascular coagulation, pulmonary embolism, and gastrointestinal fistula is due to the intra-abdominal fetal bone (Betrand et al., 2009).

The clinical symptoms of uncomplicated abdominal pregnancy are very non-specific, among which the most frequent is abdominal pain or persistent suprapubic pain, no menstruation, vaginal bleeding with discharge, gastrointestinal symptoms such as nausea and vomiting (Tolefac et al., 2017).

Diagnosis of abdominal pregnancy is due to the absence of characteristic symptoms that differentiate it from tubal pregnancy so then it requires high clinical suspicion. Investigations are needed to make a diagnosis of abdominal pregnancy such as ultrasonography (USG) and MRI. Based on the ultrasound examination reveals that a gestational sac contains a fetus outside the uterus or a mass in the pelvic and abdominal cavity contains a fetus separated

from the uterus, no visible uterine wall between the fetus and the bladder, and it is seen that the fetus is close to the abdominal wall and localization of the placenta outside the cavity of uterus. However, the accuracy of ultrasound examination is 50% with clinical symptoms. MRI examination with contrast is very helpful in making the diagnosis and knowing the involvement of other organs so that it can be additional data for the treatment of therapy in cases of abdominal pregnancy (Agarwal and Odejinmi, 2014).

The management of an abdominal pregnancy depends on the gestational age at the time of presentation and the hemodynamic state of the maternal. In early abdominal pregnancy, medical management can be given in the form of methotrexate, intracapsular injection of chloride liquid, hyperosmolar glucose, the use of prostaglandins, mifepristone, etoposide, danazol, and arterial embolization per angiography. If the maternal hemodynamic is unstable, laparoscopy to laparotomy is undertaken (Tolefac et al., 2017).

In advanced abdominal pregnancy, expectative management can be undertaken with a stable maternal hemodynamic condition and planning termination at 34 weeks of gestation (Marcellin et al., 2014; Nassali et al., 2016). If the maternal hemodynamic condition is unstable, the surgery is conducted with emergency laparotomy. The principle of surgery is to birth the fetus carefully and to identify placental implants without causing bleeding. There are two ways that can be done, namely the fetus and the placenta is removed or the fetus is removed and the placenta is left to avoid bleeding (Worley et al., 2008).¹⁰

This study aimed to reveal the diagnosis and treatment of abdominal pregnancy in Dr. Moewardi Hospital Surakarta.

CASE PRESENTATION

Case 1

A woman with G1P0A0, 20 years old, she felt that she was 7 months pregnant and she was sent by Pandan Arang Boyolali Hospital, Central Java, with a statement of her suspicion of abdominal pregnancy. The patient had no complaints such as bleeding in the birth canal or abdominal pain. From the abdominal examination, it has been found that a round hard mass was felt in the right lumbar region, extending to the upper border of the epigastric region, and the left border of the left lumbar region.

Fundal height was not palpable and fetal heart rate (+). On examination of the genitalia, the vaginal wall and pores were found within normal limits. There was also no bleeding or discharge from the birth canal. Prenatal diagnosis was carried out by ultrasound examination (USG), it has been found that extrauterine fetuses were seen in the abdominal cavity, fetal heart rate (+), across the head to the right of the right midclavicle line, the back above, the amniotic fluid was sufficient, the placenta was the impression of insertion in the anterior abdominal wall partly supra. fundus and uterine body with a lot of neurovascular features, normal size uterus, no free fluid and no congenital abnormalities.

Corticosteroid was administered for lung maturation and MgSO₄ for neuro-protectors and then it was planned termination at 34 weeks of gestation. Evaluation at 34 weeks, the mother's condition was good, there were no complaints, the fetus was in good condition, the fetal well-being was good, so that termination was planned at term of gestation with close supervision. An elective fetal evacuation laparotomy was undertaken to this patient at 37 weeks' gestation. Durante operative bleeding was 450 cc. A baby girl was born, birthweight 3,100 g, with an APGAR score of 8-9-10.

Placenta was seen measuring 20x20x2 cm insertion in the right anteroadvancedral abdominal wall, making adhesions with the bladder, uterus, omentum and descending colon, the placenta was decided to be abandoned. Length of stay the patient was 3 days in Hospital.

Case 2

A 39 year old woman, G3P2A0, 39 weeks was referred from Natalia Boyolali Hospital with an abdominal pregnancy information. The patient had no complaints such as bleeding in the birth canal or abdominal pain. From the abdominal examination, found a round hard mass in the right lumbar, fetal heart rate 155x/ m, the uterine fundus could not be palpated. On examination of the genitalia, there were no abnormalities in the vaginal wall or pores. Ultrasound examination showed a single extra-uterine fetus, head in the right lumbar area, back above. The insertion of the placenta into the anterior abdominal wall extends to the border of the uterus and bladder. Amniotic fluid volume was sufficient. Estimated fetal weight was 2,500 g. Durante operative bleeding was 100 cc. Length of stay the patient was 3 days in Hospital.

Case 3

An individual with G3P2A0, 31 years old, UK 27 weeks with complaints of abdominal pain was referred from RSUD Soetijono Blora. The patient has never had an ultrasound during this pregnancy. Based on the ultrasound examination, it was found that the uterus with EL (+) showed that the fetus was located posterior to the uterus with placental insertion in the uterine body and peritoneum in the hypochondriac region. An emergency laparotomy was undertaken for acute abdomen. Durante operative bleeding was 15,000 cc with removal of the placenta and supracervical hysterectomy. Massive transfusions were undertaken at the time of surgery. Born

baby boy, 700 grams, US 2-3-4. The condition of the mother after surgery was good.

Length of stay the patient was 8 days in Hospital.

RESULTS

Table 1. Comparison Characteristics of Abdominal Pregnancy

No	Characteristics	Case 1	Case 2	Case 3
1	Parity	G1P0A0	G3P2A0	G3P2A0
2	Age	20 y.o	39 years old	31 years old
3	Gestational age	37 weeks	39 weeks	27 weeks
4	Symptoms	Not specific	Not specific	Abdominal pain
5	Outcome	Female, birth weight 3,100 g	Female, 2,400 g	Male, 700 g
6	Placenta insitu/removed	In situ	In situ	Removed
7	MTX post operation	-	-	-
8	Placenta implantation	Vesica urinaria, omentum, uterus, descending colon	Omentum and some gynecological organs	Uterus, sigmoid colon, left tube and ovary
9	Tubal conditions	No exploration was carried out	No exploration was carried out	Stick with pregnancy products
10	Bleeding durante op	450 cc	100 cc	15,000 cc
11	Length of stay	3 days	3 days	8 days
12	Postoperative bhCG levels (mIU/ml)	08/1/2020= 11736 28/1/2020= 1881 11/2/2020= 532 10/3/2020= 41 09/4/2020= <2	30/3/2020= 12147 13/4/2020= 3804 28/4/2020= 564 11/5/2020= 41 08/6/2020= <2	-

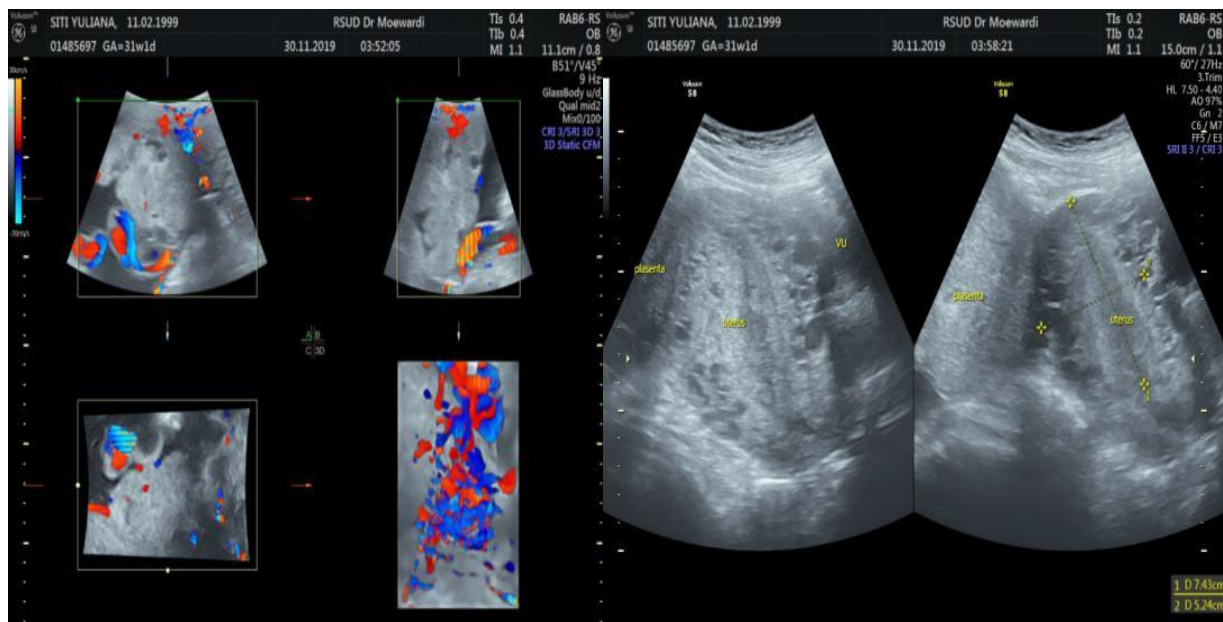


Figure 1. Ultrasound examination has revealed that partial placenta insertion in the supra fundus and uterine body with a lot of neovascular

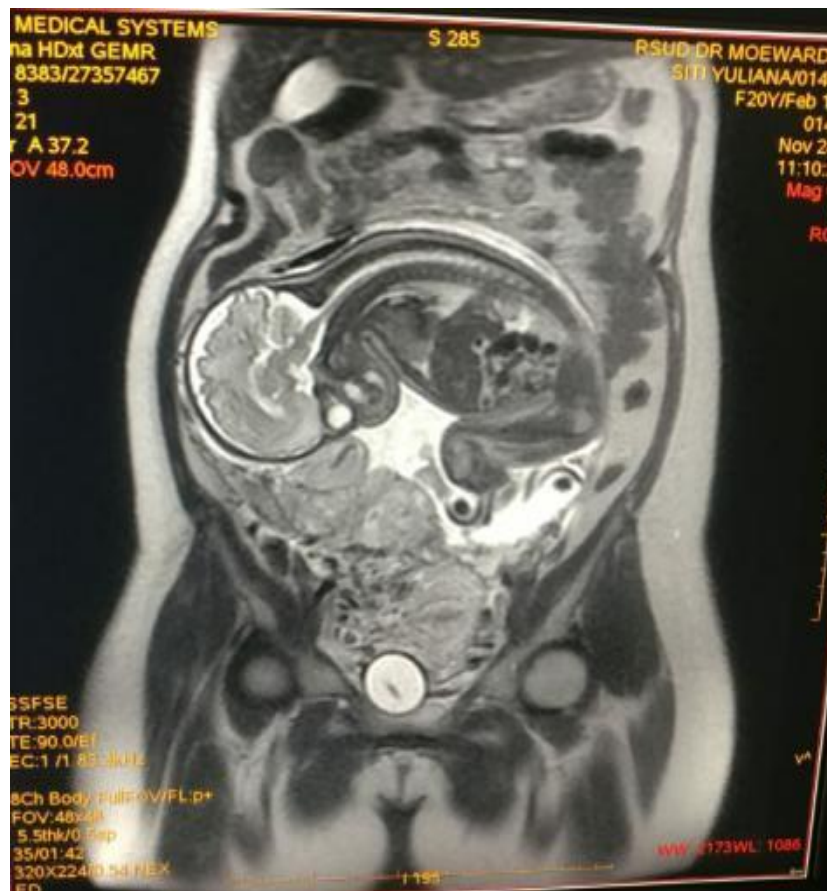

Figure 2. MRI examination supports the overview of an abdominal pregnancy by insertion of the placenta in the right anterolateral wall.

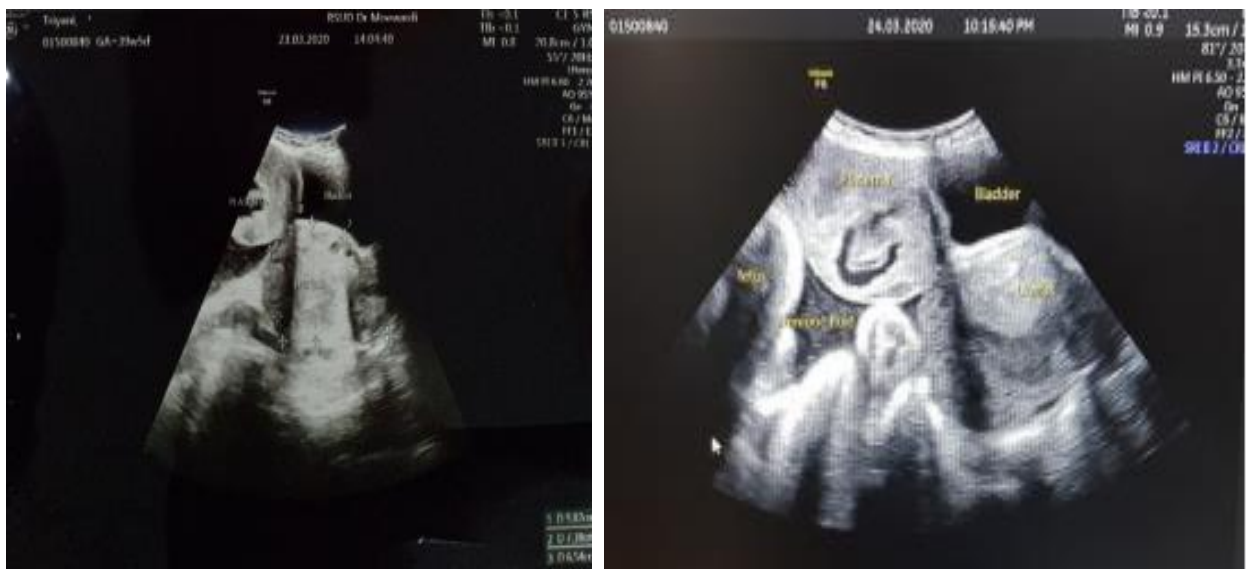

Figure 3. Ultrasound examination shows the uterus is within normal limits with the placenta that attached to the fundus uteri

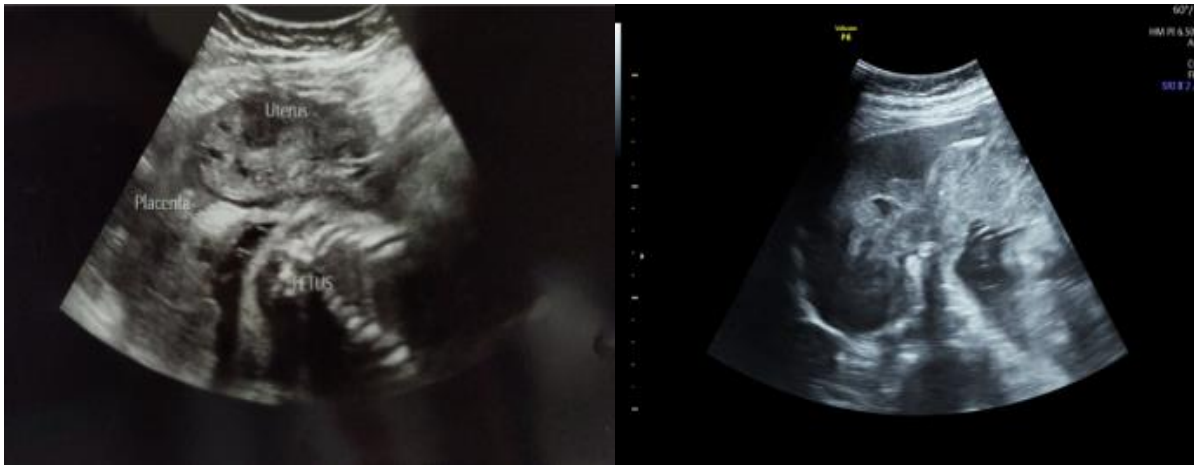

Figure 4. Ultrasound examination indicates a uterus with EL (+) with a live fetus intra-abdominal. Placenta is inserted in the posterior uterine body and peritoneum in the hypochondriac region

DISCUSSION

During 2019 - 2020, it has been found five cases of abdominal pregnancy at Dr. Moewardi Hospital Surakarta with their own unique characteristics. In general, the description of the characteristics of each abdominal pregnancy is as follows:

In all cases, the risk factors for abdominal pregnancy have not found. Parity that found was the first pregnancy and the third pregnancy. It was not known whether it was primary or secondary because there was no exploration to see the condition of both tubes.

The case of advanced abdominal pregnancy, expectative management can be undertaken where delivery is reached until term. However, if there are signs of acute abdomen, bleeding, hemodynamic unstable to be undertaken by emergency laparotomy. In cases where the placenta is removed, bleeding during the operation is significant due to adhesions to the surrounding organs. When the placenta was abandoned (in situ), methotrexate was not administered, however β -hCG levels and placental size were monitored. It obtained that an average after 3 months postoperative levels of β -hCG reached normal. The considera-

tion did not give methotrexate namely large placental necrosis after therapy can be a good medium for bacterial growth resulting in severe abdominal infections (Xu et al., 2019).

Abdominal pregnancy is a very rare case however it has high mortality and morbidity in both the mother and the fetus. Abdominal pregnancy cases are a challenge for clinicians because the symptoms and signs are not specific. Diagnosis of abdominal pregnancy is through a prenatal ultrasound supported by an MRI examination. Although expectant management is still a matter of controversy, however, it can be considered in the cases of advanced abdominal pregnancy under certain conditions. Placenta management either abandoned in situ or removed has its own advantages and disadvantages. The evaluation of an abandoned placenta without methotrexate has indicated good outcome in cases of abdominal pregnancy.

AUTHOR CONTRIBUTION

Uchti Akbar, Nutria Widya Purna Angraini, Eric Edwin Yuliantara, M. Adrianes Bachnas, Robert Ridwan, Sri Sulistyowati contributed to the design and implementa-

tion of the study, analysis of the results and writing of the manuscript.

CONFLICT OF INTEREST

The authors state that there was no conflict of interest either in terms of material or other.

FUNDING AND SPONSORSHIP

The author declares no funding sources.

ACKNOWLEDGEMENT

The author's gratitude to the Department of Obstetrics and Gynaecology Dr. Moewardi Hospital who have supported this research.

REFERENCE

- Agarwal N, Odejinmi F (2014). Early abdominal ectopic pregnancy: challenges, update and review of current management. *Obstet Gynaecol.* 16(3): 193-198. doi: 10.1111/tog.12109
- Bertrand G, Le RC, Simard-Émond L, Dubois J, Leduc L (2009). Imaging in the management of abdominal pregnancy: a case report and review of the literature. *J Obstet Gynecol Can.* 31(1): 57-62. doi: 10.1016/s1701-2163-(16)34055-5
- Gilani S, Syed M, (2019). A case of advanced abdominal pregnancy with viable fetus at term. *J Med Sci.* 27(2): 147-149.
- Hailu FG, Yihunie GT, Essa AA, Tsega KW (2017). Advanced abdominal pregnancy, with live fetus and severe pre-eclampsia, case report. *BMC Pregnancy Childbirth* 17(1): 1-4. doi: 10.1186/s12884-017-1437
- Jabbar NAA, Saquib S, Mohammed Talha, WE (2018). Successful Management of Abdominal Pregnancy: Two Case Reports. *Oman Med J.* 33(2): 171-175. doi: 10.5001/omj.2018.32
- Marcellin L, Ménard S, Lamau MC, Mignon A, Aubelle M, Grangé G, Goffinet F (2014). Conservative Management of an Advanced Abdominal Pregnancy at 22 Weeks. *Am J Perinatol Rep* 4(01): 055-060. doi: 10.1055/s-0034-13717-49.
- Nassali MN, Benti TM, Bandani-Ntsabele, M, Musinguzi E (2016). A case report of an asymptomatic late term abdominal pregnancy with a live birth at 41 weeks of gestation. *BMC Res Notes.* 9(1). doi:10.1186/s13104-016-1844-6
- Tolefac PN, Abanda MH, Minkande JZ, Priso EB (2017). The challenge in the diagnosis and management of an advanced abdominal pregnancy in a resource-low setting: a case report. *J Med Case Rep.* 11(1):199. doi: 10.1186/s13256-017-1369-1.
- Worley KC, Hnat MD, Cunningham FG (2008). Advanced extrauterine pregnancy: diagnostic and therapeutic challenges. *Am J Obstet Gynecol.* 198(3): 297.e1-297.e7. doi: 10.1016/j.ajog.2007.09.044.
- Xu L, Xiang Z, Wu T, Feng S (2019). Advanced Abdominal Pregnancy with Retained Placenta and Methotrexate-Induced Severe Bone Marrow Suppression: A Case Report. *Biomed J Sci Technol Res.* 19: 14487-14488. doi: 10.26717/BJSTR.2019.19.003341